

# Chromoblastomycosis as a mimicker of neoplastic lesion: A case report

Manisha Sarkar, Dipanwita Das, Anindita Sinhababu

Department of Pathology, College of Medicine & JNM Hospital, Kalyani, Nadia, West Bengal, India

Correspondence to: Manisha Sarkar, E-mail: drmanishasarkar@gmail.com

Received: September 21, 2016; Accepted: October 05, 2016

## ABSTRACT

Chromoblastomycosis, a rare fungal infection, occurs most commonly in tropical and subtropical countries. Persons involved in agricultural works are most commonly affected. Traumatic injury by contaminated wood particles/thorn predispose to chromoblastomycosis. We are reporting a case of chromoblastomycosis in a 50-year-old male presenting with a nodular swelling in the right foot for 2 months. It was clinically suspected to be a neoplastic lesion and was subjected to surgical excision and histopathological examination that demonstrated the presence of fungal hyphae, spores, and the typical “sclerotic bodies.” Surgical excision is not needed in chromoblastomycosis as it can be treated by antifungals. Chromoblastomycosis needs to be considered in the initial differential diagnosis of verrucous cutaneous lesions of foot, particularly in agricultural workers.


**KEY WORDS:** Chromoblastomycosis; Fungal Infection; Sclerotic Body

## INTRODUCTION

The dematiaceous fungi/pigmented fungi constitute a clinically important group of fungi. There are two clinicopathological groups – chromoblastomycosis and phaeohyphomycosis, which represent extremes of a continuum of infections.<sup>[1]</sup> Chromoblastomycosis is characterized by the presence of “sclerotic body” in the tissues. Phaeohyphomycosis is a collective term for a heterogeneous group of opportunistic fungal infections that contain dematiaceous yeast-like cells and hyphae. These infections are seen following direct implantation of infected wood particles, soil. In immunocompromised patients, the portal of entry is not always evident.

The disease is worldwide in distribution. The exact prevalence and incidence of chromoblastomycosis are unknown because of sporadic case reports. However, most of the reported cases are from humid tropical and subtropical countries of America, Asia, and Africa.<sup>[2]</sup> The highest prevalence rates are reported in Mexico, Cuba, Venezuela, the Dominican Republic, Colombia, and Brazil. In Africa, most of the cases have been reported in Madagascar and in South Africa. In Asia Japan, Sri Lanka and China dominate the picture.<sup>[3,4]</sup> Exact prevalence in India is not known because of infrequent reports. The disease is not so uncommon in India. In 1967, Indian scenario was reviewed by Mohapatra et al.<sup>[5]</sup> Occasional cases are being reported from different parts of the country.<sup>[5,6]</sup>

The clinical presentation of chromoblastomycosis is often misleading. It presents as solid nodule, tumor, verrucous plaque, or warty papule.<sup>[1]</sup> In most of the cases, the history of injury by vegetable particles/thorn is missed. It is often mistaken as tuberculosis (TB), leprosy, and even neoplasm, which can lead to mismanagement. Correct diagnosis of a fungal infection can eliminate the risk of radical excision, as here antifungals (itraconazole and fluconazole) with or without potassium iodide would only suffice.<sup>[5]</sup>

| Access this article online   |   |
|--|---|
| Website: <a href="http://www.ijmsph.com">http://www.ijmsph.com</a> | Quick Response code   |
| DOI: 10.5455/ijmsph.2017.1057605102016                             |  |

International Journal of Medical Science and Public Health Online 2016. © 2016 Manisha Sarkar et al. This is an Open Access article distributed under the terms of the Creative Commons Attribution 4.0 International License (<http://creativecommons.org/licenses/by/4.0/>), allowing third parties to copy and redistribute the material in any medium or format and to remix, transform, and build upon the material for any purpose, even commercially, provided the original work is properly cited and states its license.

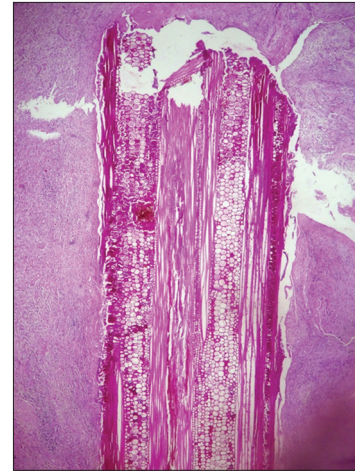
We are reporting the case because it was clinically suspected to be a neoplastic lesion. It was surgically excised and subjected to histopathological examination. Although there was no history of previous fine-needle aspiration cytology (FNAC) of the lesion, correct diagnosis by FNAC could have avoided the tissue loss due to surgical excision. We are emphasizing on the fact that consciousness about chromoblastomycosis among clinicians as well as pathologists could simplify the management strategy and provide relief from mental stress to the patients as well as the relatives.

## CASE REPORT

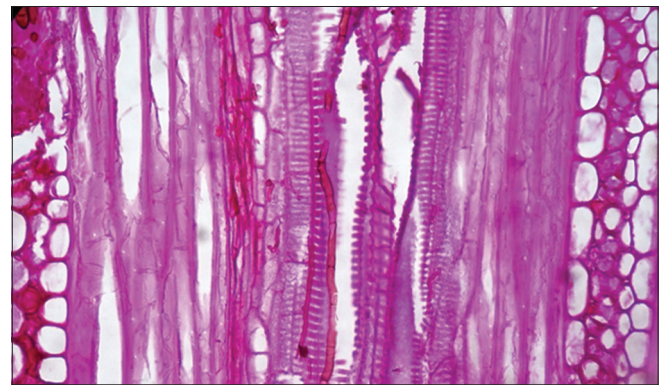
A 50-year-old male, agricultural worker, presented with a solid nodular lesion of right foot on the extensor surface for 2 months. He was treated by local doctors but with no improvement. There was a history of trauma before the swelling. The lesion was slowly enlarging in size and was firm to hard in appearance. The routine hematological and biochemical parameters were within normal limits. Suspecting the lesion a neoplastic one, surgical excision and histopathological examination were undertaken. Macroscopically, the specimen was a single piece of partially skin covered grayish white globular tissue, measuring 1.8 cm × 1.2 cm × 0.2 cm. Cut section of the tumor showed solid, firm, and whitish tissue having multiple points of necrosis. All the sections were formalin fixed, paraffin embedded, and processed for histopathological examination. The routine Hematoxylin and Eosin (H and E) stained microsections showed acanthosis of the overlying skin. Numerous ill-formed granulomas with multinucleated foreign-body type of giant cells were seen in the sub-epidermal connective tissue. Aggregates of histiocytes, neutrophilic microabscess were noted. An important finding was the presence of a piece of vegetable material within a sinus tract (Figure 1). On close scrutiny light brown pigmented and septate fungal hyphae were noted both within as well as outside the vegetable cells (Figure 2). There was also presence of rounded, thick-walled, and dark brown pigmented sclerotic bodies. The fungal spores were arranged singly as well as in small clusters. The spores showed the presence of intracellular longitudinal wall formation (Figure 3). Periodic acid–Schiff stained section demonstrated the presence of fungus. No evidence of any dysplasia/malignancy was noted in the lesion. The histopathological diagnosis was chromoblastomycosis in a case that was clinically suspected to be a neoplastic lesion.

## DISCUSSION

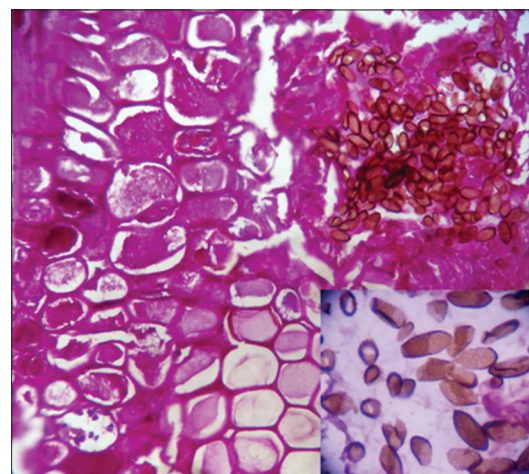
Chromoblastomycosis, a non-contagious disease, is caused by saprophytic, pigmented fungi commonly isolated from plant debris and soil. Hence, it can be an occupational hazard in some rural workers. They normally contain melanin pigment that gives them deep brown color.<sup>[1]</sup> Several species have been described such as *Fonsecaea pedrosoi*, *Phialophora compacta*, *Phialophora verrucosa*, *Cladosporium carrionii*,



**Figure 1:** Microsection showing vegetable matter within tissue section (H and E, ×100)



**Figure 2:** Microsection showing dark brown, pigmented, and septate fungal hyphae (H and E, ×400)



**Figure 3:** Microsection showing pigmented sclerotic bodies within the vegetable cells. Inset: Intracellular wall formation in the sclerotic bodies (H and E, ×400)

*Aureobasidium pullulans*, and *Rhinocladiella aquaspersa*. *Exophiala spinifera* and *Chaetomium funicola* are also included. *F. pedrosoi* is the most commonly isolated organism.<sup>[1]</sup> The genera which have been commonly described in Indian scenario are *Exophiala*, *Phialophora*, *Cladosporium*, *Curvularia*, *Fonsecaea*, and *Alternaria*.<sup>[6-9]</sup>

Max Rudolph 1<sup>st</sup> described chromoblastomycosis in 1914, in Brazil.<sup>[2,10]</sup> In 1915, Medlar reported chromoblastomycosis in an Italian immigrant in Boston.<sup>[2]</sup> He described the “sclerotic body,” which was later named as “Medlar body.”<sup>[2]</sup> It is also termed as “copper penny body” or “muriform cells.” In India, such cases are being reported from the sub-Himalayan belt and the coastal areas due to hot and humid climate.<sup>[11-13]</sup>

This small tiny fungus is causing disease when they are inoculated by contaminated soil/wood particles into tissue. The histopathological findings of cutaneous chromoblastomycosis consist of acanthosis, pseudoepitheliomatous hyperplasia, dermal microabscess, chronic granulomatous inflammation, multinucleated foreign body type of giant cells, “sclerotic body”/“copper penny body.” Primary lesion develops at the site of inoculation usually at an extremity and remains localized for years. Spread to multiple sites may occur following autoinoculation. Lymphatic and hematogenous spread may rarely develop producing elephantiasis. Long standing cases may even convert to squamous cell carcinoma.<sup>[2]</sup> In the present case, the patient may have acquired the infection following some trauma as evidenced by the presence of vegetable particle within the tissue. Histopathological microsections demonstrated the presence of ill-formed granulomas, aggregates of histiocytes, multinucleated giant cells. The presence of sclerotic body, septate hyphae, intracellular wall in the spores, and the vegetable cells confirmed that the chromoblastomycosis infection occurred following inoculation of contaminated wood particle. As they are naturally pigmented fungi containing melanin, they can be easily identified in H and E stained section. Thereby the unnecessary cost of special fungal stains can be avoided.

Clinical presentation of chromoblastomycosis is nodular swelling in an agricultural worker that may or may not be accompanied with a history of trauma. Hence, they may be confused with TB verrucosa cutis, leprosy, squamous cell carcinoma, sporotrichosis, and palmar-plantar psoriasis.<sup>[13,14-16]</sup> This case was clinically suspected to be a neoplastic one. The diagnosis of chromoblastomycosis gave tremendous relief to the patient as well as the treating physician. Treatment of chromoblastomycosis is antifungal agents. In previous days, radical mutilating surgery was the only treatment. With the introduction of Itraconazole, therapy management of chromoblastomycosis became easier.

## CONCLUSION

We conclude that chromoblastomycosis should be kept under consideration during assessment of verrucous cutaneous lesions, especially on the extremity. Close search for fungal hyphae, spores in the lesion would help to find out the characteristic “copper penny” bodies in verrucous cutaneous lesions having pseudoepitheliomatous hyperplasia and

abscesses. High index of suspicion could guide to make the diagnosis confidently.

## REFERENCES

1. Weedon D. Mycoses and algal infection. In: Weedon D, editor. *Weedon's Skin Pathology*. 3<sup>rd</sup> ed. China: Churchill Livingstone Elsevier; 2010. p. 596-7.
2. Krzysciak PM, Pindycka-Piaszczyńska M, Piaszczyński M. Chromoblastomycosis. *Postepy Dermatol Alergol* 2014;31(5):310-21.
3. Ripon WJ. Chromoblastomycosis. In: *Medical Mycology: The Pathogenic Fungi and the Pathogenic Actinomycetes*. 3<sup>rd</sup> ed. Philadelphia, PA: Saunders W.B; 1988. p. 276.
4. Kwon-Chung KJ, Bennett JE. Chromoblastomycosis. In: *Medical Mycology*. Pennsylvania: Lea and Febiger; 1992. p. 337.
5. Sharma NL, Sharma RC, Grover PS, Gupta ML, Sharma AK, Mahajan VK. Chromoblastomycosis in India. *Int J Dermatol*. 1999;38(11):846-51.
6. Sharma A, Hazarika NK, Gupta D. Chromoblastomycosis in sub-tropical regions of India. *Mycopathologia*. 2010;169(5):381-6.
7. Sharma NL, Mahajan V, Sharma RC, Sharma A. Subcutaneous phaeohyphomycosis in India--a case report and review. *Int J Dermatol*. 2002;41(1):16-20.
8. Angadi KM, Mishra RN, Gandham NR, Moumita S, Singhania SS, Jadhav SV. Chromoblastomycosis: A rare case of infection by *Fonsecaea compacta* from Western Maharashtra, India. *Int J Microbiol Res*. 2012;4(9):330-1
9. Momin YA, Raghuvanshi SR, Lanjewar DN. Cutaneous chromoblastomycosis. *Bombay Hosp J*. 2008;50(2):299-301.
10. Castro RM, Castro LG. On the priority of description of chromomycosis. *Mykosen*. 1987;30(9):397-403.
11. Chander J. Chromoblastomycosis. In: *Textbook of Medical Mycology*. 3<sup>rd</sup> ed. New Delhi: Mehta Publisher; 2009. p. 175-86.
12. Mohanty L, Mohanty P, Padhi T, Samantray S. Verrucous growth on leg. *Indian J Dermatol Venereol Leprol*. 2006;72(5):399-400.
13. Pradhan SV, Talwar OP, Ghosh A, Swami RM, Shiva Raj KC, Gupta S. Chromoblastomycosis in Nepal: A study of 13 cases. *Indian J Dermatol Venereol Leprol*. 2007;73(3):176-8.
14. Pradeepkumar NS, Joseph NM. Chromoblastomycosis caused by *Cladophialophora carrionii* in a child from India. *J Infect Dev Ctries*. 2011;5(7):556-60.
15. Bandyopadhyay A, Majumdar K, Gangopadhyay M, Banerjee S. Cutaneous chromoblastomycosis mimicking tuberculosis verrucosa cutis: Look for copper pennies! *Turk Patoloji Derg*. 2015;31(3):223-5.
16. De A, Gharami RC, Datta PK. Verrucous plaque on the face: What is your diagnosis? *Dermatol Online J*. 2010;16(1):6.

**How to cite this article:** Sarkar M, Das D, Sinhababu A. Chromoblastomycosis as a mimicker of neoplastic lesion: A case report. *Int J Med Sci Public Health* 2017;6(3):659-661.

**Source of Support:** Nil, **Conflict of Interest:** None declared.